

# The first clinical case of dry age-related macular degeneration treated with photobiomodulation and nutraceuticals: a protocol proposal

R. Pinelli, M. Bertelli, E. Scaffidi

Switzerland Eye Research Institute, Lugano, Switzerland.

Corresponding Author: Roberto Pinelli, MD; e-mail: pinelli@seri-lugano.ch

**Keywords:** AMD, LLLT, PBM, Age-related macular degeneration, Photobiomodulation, Low-level light therapy, Nutraceuticals, Lutein, Vaccinium Myrtillus, Anthocyanins.

## ABSTRACT

The purpose of this protocol proposal is to suggest a new non-invasive combined therapeutic approach for dry age-related macular degeneration (AMD), an eye disease with no approved treatment or cure. A nutraceutical approach involving dietary supplementation of antioxidants can reduce its risk. Also, photobiomodulation (PBM, or LLLT) has shown promising results with the advantage of non-invasiveness. We present a clinical case study which combines a nutraceutical approach with photobiomodulation. Nine PBM cycles were administered to the patient over one month, and lutein, resveratrol and Vaccinium myrtillus supplements for three months. After one month and after six months, the OCT showed reduced drusen. The patient obtained subjectively improved vision, less eye strain, more color contrast, higher definition and a better far and near uncorrected visual acuity. Amsler grid test was regular. Contrast sensitivity improved from 1.8 to 2.0. Outcomes remained stable at the 6-month follow-up.

This case demonstrated a successful non-invasive treatment with improved quality of vision in dry AMD. A larger population followed over a long-term period is warranted. Irradiation, along with the support of nutraceuticals, could therefore offer a new non-invasive, adverse-effect-free means of stimulating retinal stem cells to regenerate.

## ABBREVIATIONS

AMD (age-related macular degeneration); OCT (optical coherence tomography); RE (right eye); LE (left

eye); UCVA (uncorrected visual acuity); BCVA (best-corrected visual acuity); PBM (photobiomodulation); LEDs (light-emitting diodes).

## INTRODUCTION

Age-related macular degeneration (AMD) is an eye disease that leads to vision loss and can cause blindness. AMD can be classified into two major forms: dry AMD (also known as atrophic form) and wet AMD (also known as exudative or neovascular form). The dry form affects 80% of individuals with AMD; it tends to progress more slowly than the wet type, and results in a subsequent loss of visual acuity<sup>1</sup>. At the moment there is no approved treatment or cure for this disease (dry form).

In dry AMD, small white or yellowish deposits, called “drusen”, form beneath the macula (the central area of the retina), causing a progressive loss of central vision over time.

Evidence-based studies have been showing over the years that the risk of progressive macular degeneration can be reduced through the consumption of antioxidants such as xanthophylls, flavonoids and anthocyanins<sup>2-6</sup>.

Moreover, several studies with strong and moderate evidence in the last 5 years have shown encouraging results in treating eye diseases (age-related macular degeneration, retinopathy of prematurity, diabetic macular edema) with a technique known as photobiomodulation (PBM)<sup>7-12</sup>. Photobiomodulation has also been used in the last 20 years for musculoskeletal pain, injury and dysfunction, wound healing, to improve acute muscle performance and reduce muscle damage after exercise<sup>7</sup>, for neuropathic pain, lymphedema and oral mucositis<sup>13-15</sup>.

Photobiomodulation, or low-level light therapy, is an application of monochromatic light to a part of the body with the aim of repairing tissues, and reducing inflammation, edema and pain<sup>7</sup>. It is not a heat therapy, it is more akin to photosynthesis in plants. Light, in the far red and near-infrared spectral range, can stimulate the cells and leads to a cascade of photochemical reactions. First the low-powered light is absorbed locally by the cytochrome c oxidase; mitochondrial energy is then produced by releasing oxygen, which results in increased ATP concentration and reduced oxidative stress. This photochemical reaction then activates enzymes and second messengers which lead to a cellular and, indirectly, a systemic response by tissues that have not absorbed photons<sup>11,13,14</sup>.

PBM can be used in acute and chronic eye diseases, such as dry AMD, since mitochondrial dysfunction and oxidative stress play a key role in many macular diseases<sup>1,7,11</sup>. PBM does not worsen the disease, has no side effects and is completely non-invasive<sup>1,15</sup>.

## MATERIALS AND METHODS

The patient underwent a clinical protocol, which we would propose as the “Lugano protocol”.

Our proposed protocol provides a combination of nine PBM therapy cycles and a simultaneous dietary supplementation with antioxidants in the form of nutraceuticals (three natural extracts in powder form).

PBM was performed through a medical device (Valeda light delivery system) which applied light-emitting diodes (LEDs) to stimulate cellular function and improve energy production. Each cycle of therapy delivered wavelengths in the range between 590 nm and 850 nm for 4 minutes per eye.

In parallel with PBM therapy, the dietary supplementation consisted of 5 g per day of 3 antioxidants in powder form: lutein from *Tagetes erecta*, resveratrol from *Polygonum cuspidatum* and *Vaccinium myrtillus*.

The procedure was performed without changing the dietary regimen of the patient.

The PBM cycles were completed in approximately one month.

The patient continued the supplementation with nutraceuticals for an overall period of 3 months. Supplements were administered for 20 days during each month.

## OUTCOME MEASURES

Clinical outcomes were determined using the following measures:

- OCT macular scan machine (imaging test)
- Amsler grid to measure the quality of the visual field (detection of missing or blurred areas; wavy, broken or distorted lines)
- Pelli-Robson chart for assessment of contrast sensitivity
- Snellen chart for far visual acuity (UCVA and BCVA)
- Jaeger chart for near visual acuity (UCVA and BCVA)

The clinical outcomes were measured at the end of the PBM procedure, after three months and after six months.

The patient had been informed about the non-invasive nature of the procedure, the risks and the benefits, the alternative options for treatment of dry AMD, and signed an informed consent form.

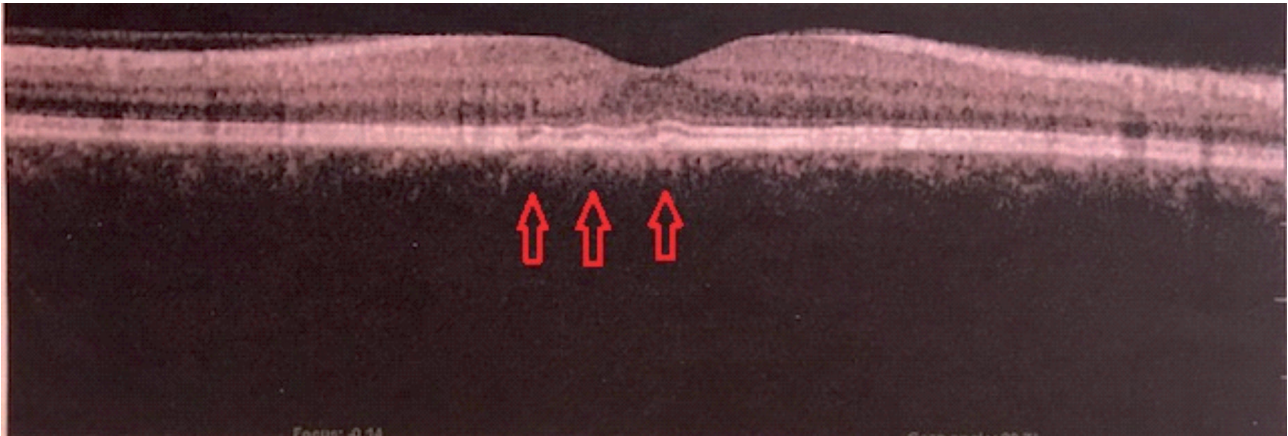
## CASE PRESENTATION

A 53-year-old healthy male was diagnosed with initial dry AMD in his LE about two years previously. He used to wear only reading glasses. The main complaint of the patient was that he had a lower quality of vision, a loss of definition and eye strain in his LE and a disparity of vision between RE and LE. The eye performance at work was impaired, especially while the patient was reading and using the laptop. Eye strain was frequent even with the use of reading glasses.

His far UCVA was RE 20/20 and LE 20/25 (not improved with lens or pinhole). His near UCVA was RE J2 and LE J2-J3; his near BCVA was RE J1 and LE J1-J2. The OCT scan revealed a normal macular profile in the RE and small deposits (drusen) beneath the macula in the LE (Figure 1). The contrast sensitivity was 2.0 in the RE, and 1.8 in the LE. The Amsler grid test was negative for the RE and showed slightly irregular lines for the LE. The proposed protocol was applied to the LE of the patient with the patient's consent.

## RESULTS

From an objective point of view, the OCT scan showed a decreased number of drusen in the central



**Figure 1.** Left eye macular profile before treatment. Red arrows indicate drusen before treatment.

area of the macula and thus a more regular macular profile in the LE (Figure 2) after one month.

From a subjective point of view, the patient reported improved vision after treatment. Less eye strain, more color contrast, higher definition, less disparity between RE and LE and better near visual acuity without glasses were noticed.

The Amsler grid test revealed a regular grid with no wavy lines. The contrast sensitivity test indicated an improvement from 1.8 to 2.0 in the LE. The far UCVA was 20/20 in both eyes and near UCVA improved from J3 to J1-J2 in the LE, near BCVA improved from J1-J2 to J1 in the LE.

The same clinical outcomes were measured at 3 months and 6 months after treatment.

The eye condition was stable and unchanged, and no worsening of the outcomes were noticed after 6 months.

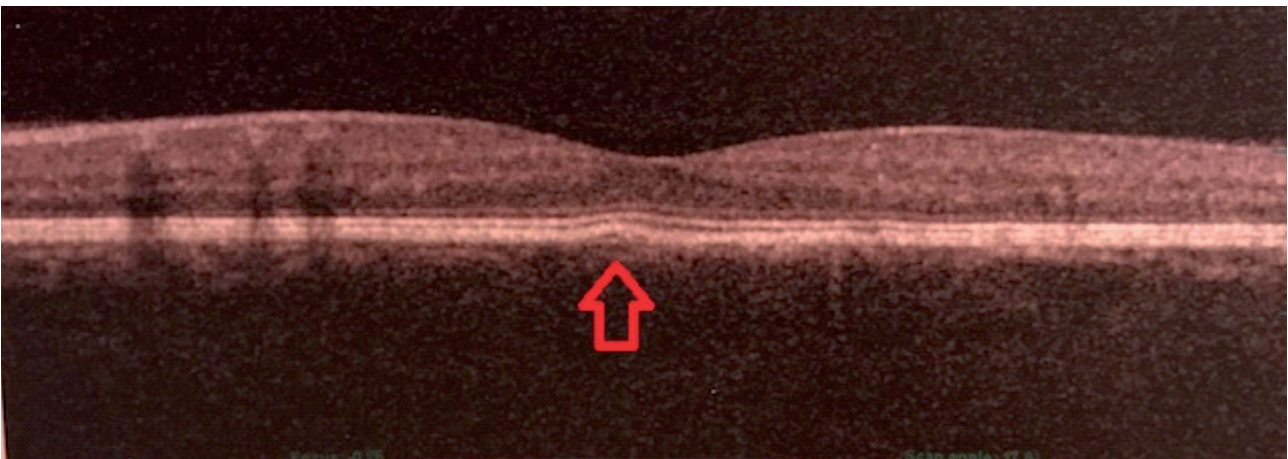
## DISCUSSION

This case report demonstrated a successful treatment whereby quality of vision was improved and not worsened in a patient suffering from dry AMD; a better visual acuity, contrast sensitivity and a less damaged macular profile were observed.

Overall, these results are encouraging and indicate the way toward consolidating our proposed Lugano protocol in the future. It may start from a single case, but it will form part of a larger project.

To confirm the efficacy of this approach, long-term randomized controlled trials conducted on patients with dry AMD are, therefore, warranted.

Promoting cellular regeneration by combining light waves and nutraceuticals represents a challenge in ophthalmology. To date, there are no approved theories for many retinal diseases. Intrigu-



**Figure 2.** Left eye macular profile 1 month after the initiation of PBM treatment. Red arrow indicates the decreased number of drusen observed after treatment.

ingly, this protocol seems to offer an extremely promising approach to prevent visual acuity from worsening and to promote tissue repair in the dry form of AMD. Moreover, this approach has the enormous advantage of being entirely non-invasive.

According to this hypothesis, irradiation at certain wavelengths, combined with antioxidants intake in the form of nutraceuticals, can regenerate retinal cells.

## CONCLUSIONS

Modulated light combined with antioxidants consumption in the form of nutraceuticals could offer a novel valid therapeutic approach for dry AMD, which may potentially facilitate the repair of damaged tissues in the retina and promote survival and functions of epithelial cells within the retinal pigmented epithelium<sup>16</sup>.

## CONFLICT OF INTEREST:

All authors declare that there are no conflicts of interest regarding the publication of this manuscript.

## REFERENCES

1. Markowitz SN, Devenyi RG, Munk MR, Croissant CL, Tedford SE, Rückert R, Walker MG, Patino BE, Chen L, Nido M, Tedford CE. A double-masked, randomized, sham-controlled, single-center study with photobiomodulation for the treatment of dry age-related macular degeneration. *Retina* 2019 Aug 9. doi: 10.1097/IAE.0000000000002632. [Epub ahead of print]
2. Forte R, Cennamo G, Finelli ML, Bonavolontà P, de Crecchio G, Greco GM. Combination of flavonoids with *Centella asiatica* and *Melilotus* for diabetic cystoid macular edema without macular thickening. *J Ocul Pharmacol Ther.* 2011; 27: 109-113.
3. Khoo HE, Ng HS, Yap WS, Goh HJH, Yim HS. Nutrients for prevention of macular degeneration and eye-related diseases. *Antioxidants (Basel)* 2019; 8: E85.
4. Pawlowska E, Szczepanska J, Koskela A, Kaarniranta K, Blasiak J. Dietary polyphenols in age-related macular degeneration: protection against oxidative stress and beyond. *Oxid Med Cell Longev* 2019; 2019: 9682318.
5. Riva A, Togni S, Franceschi F, Kawada S, Inaba Y, Eggenhoffner R, Giacomelli L. The effect of a natural, standardized bilberry extract (Mirtoselect®) in dry eye: a randomized, double blinded, placebo-controlled trial. *Eur Rev Med Pharmacol Sci* 2017; 21: 2518-2525.
6. Tao Y, Chen T, Yang GQ, Peng GH, Yan ZJ, Huang YF. Anthocyanin can arrest the cone photoreceptor degeneration and act as a novel treatment for retinitis pigmentosa. *Int J Ophthalmol* 2016; 9: 153-158.
7. Hamblin MR. Photobiomodulation or low-level laser therapy. *J Biophotonics* 2016; 9: 1122-1124.
8. Merry G, Devenyi, R, Dotson R, Markowitz S, Reyes S. Treatment of dry age-related macular degeneration with photobiomodulation. Presented at The Association for Research and Vision in Ophthalmology (Fort Lauderdale) 2012.
9. Natoli R, Valter K, Barbosa M, Dahlstrom J, Rutar M, Kent A, Provis J. 670nm photobiomodulation as a novel protection against retinopathy of prematurity: evidence from oxygen induced retinopathy models. *PLoS One* 2013; 8: e72135.
10. Tang J, Herda AA, Kern TS. Photobiomodulation in the treatment of patients with non-center-involving diabetic macular oedema. *Br J Ophthalmol* 2014; 98: 1013-1015.
11. Ferraresi C, Kaippert B, Avci P, Huang YY, de Sousa MV, Bagnato VS, Parizotto NA, Hamblin MR. Low-level laser (light) therapy increases mitochondrial membrane potential and ATP synthesis in C2C12 myotubes with a peak response at 3-6 h. *Photochem Photobiol* 2015; 91: 411-416.
12. Koev K, Avramov L, Borissova E. Clinical results from low-level laser therapy in patients with autosomal dominant cone-rod dystrophy. *Journal of Physics: Conference Series, Volume 992, 20th International Summer School on Vacuum, Electron and Ion Technologies 25-29 September 2017, Sozopol, Bulgaria.*
- 13) Holanda VM, Chavantes MC, Wu X, Anders JJ. The mechanistic basis for photobiomodulation therapy of neuropathic pain by near infrared laser light. *Lasers Surg Med* 2017; 49: 516-524.
- 14) Baxter GD, Liu L, Petrich S, Gisselman AS, Chapple C, Anders JJ, Tumilty S. Low level laser therapy (Photobiomodulation therapy) for breast cancer-related lymphedema: a systematic review. *BMC Cancer* 2017; 17: 833.
- 15) Zadik Y, Arany PR, Fregnani ER, Bossi P, Antunes HS, Bensadoun RJ, Gueiros LA, Majorana A, Nair RG, Ranna V, Tissing WJE, Vaddi A, Lubart R, Migliorati CA, Lalla RV, Cheng KKF, Elad S; Mucositis Study Group of the Multinational Association of Supportive Care in Cancer/International Society of Oral Oncology (MASCC/ISOO). Systematic review of photobiomodulation for the management of oral mucositis in cancer patients and clinical practice guidelines. *Support Care Cancer* 2019; 27: 3969-3983.
- 16) Saini JS, Temple S, Stern JH. Human Retinal Pigment Epithelium Stem Cell (RPESC). *Adv Exp Med Biol* 2016; 854: 557-562.